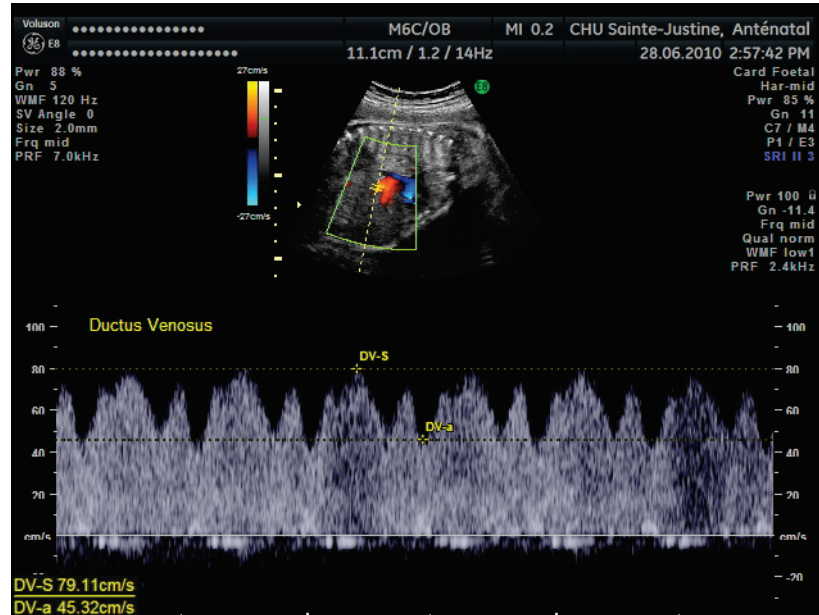


## Ductus venosus

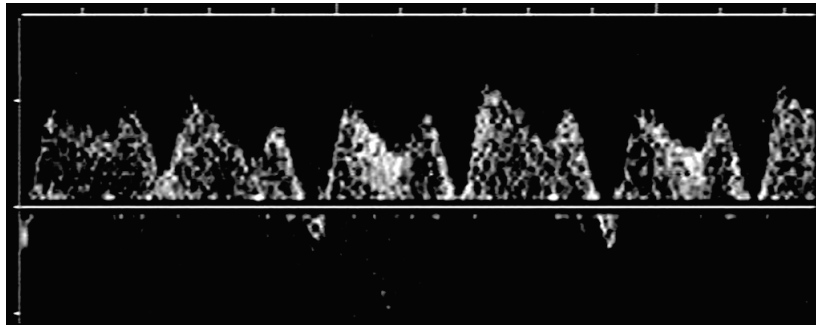
### Normal recording

#### Positive wave



### Abnormal recordings

#### Nil wave



#### Inverted wave

