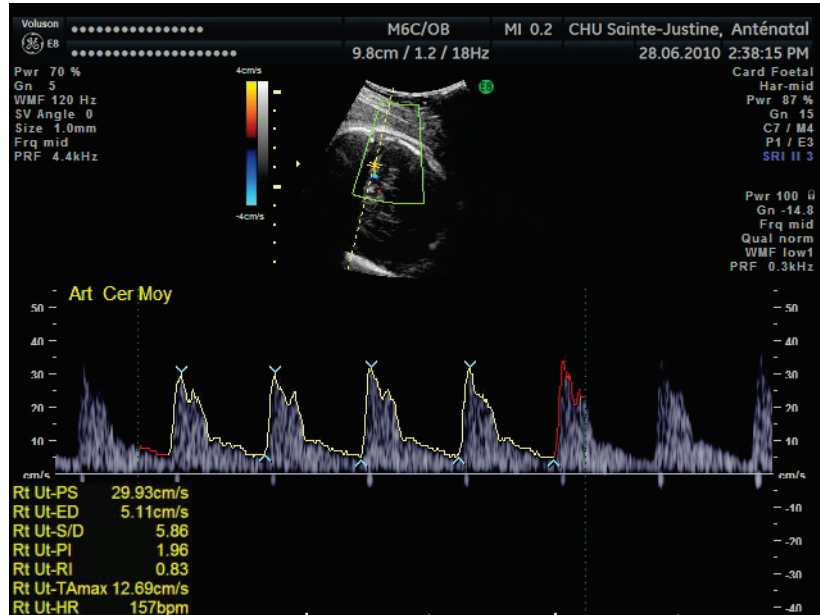


Middle cerebral artery

Normal recording

Normal diastolic flow



Abnormal recording

Increased diastolic flow

