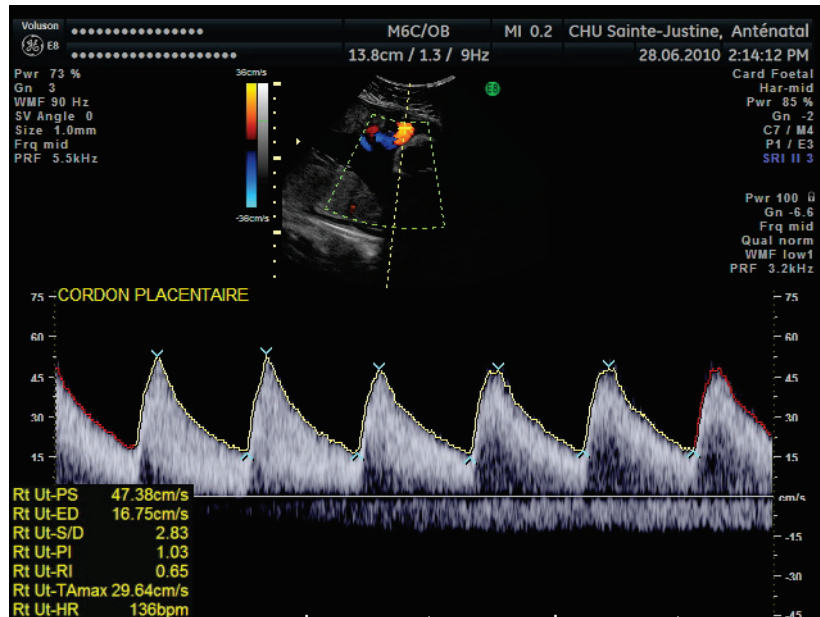


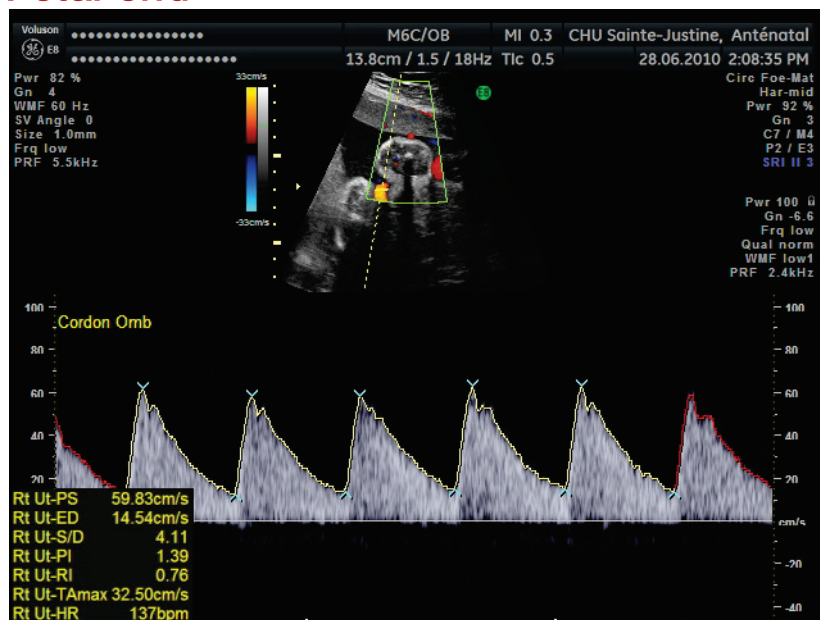
Umbilical artery

Normal recordings

Placental end



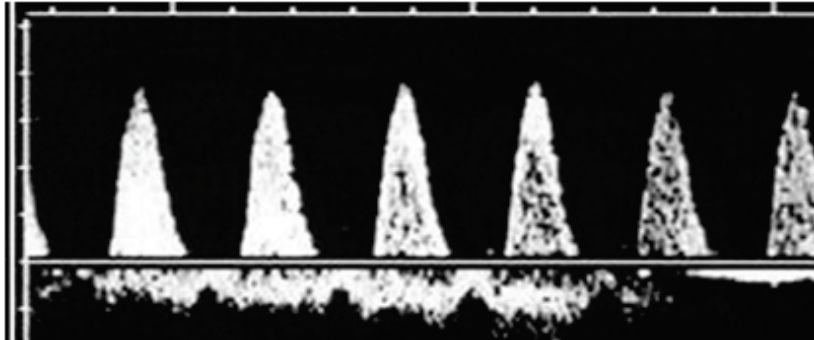
Fetal end



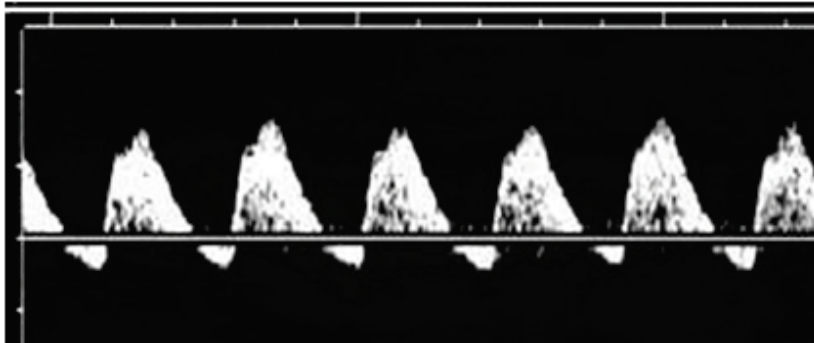
PIAF study: Placental insufficiency and aortic isthmus flow

Abnormal recordings

Absent diastolic flow



Retrograde flow, telediastolic



Retrograde flow, holodiastolic

