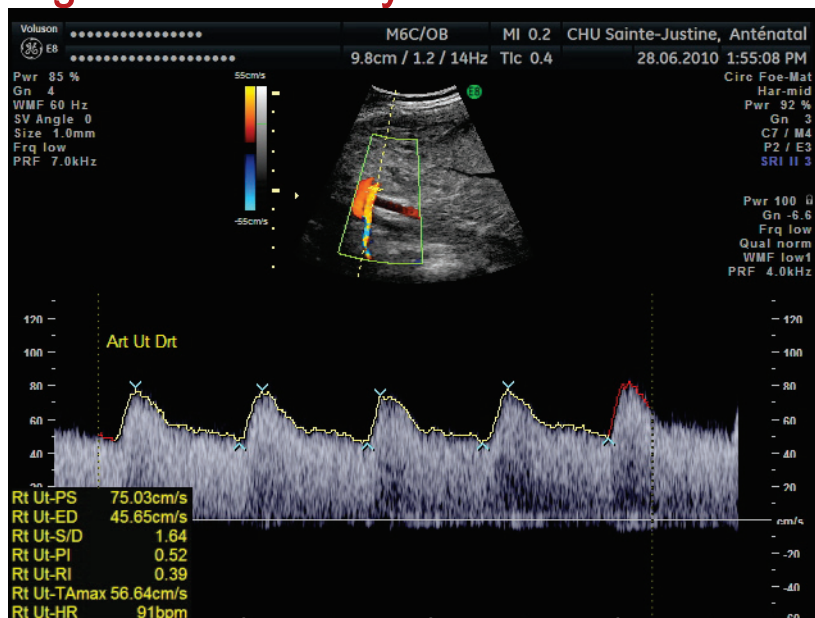


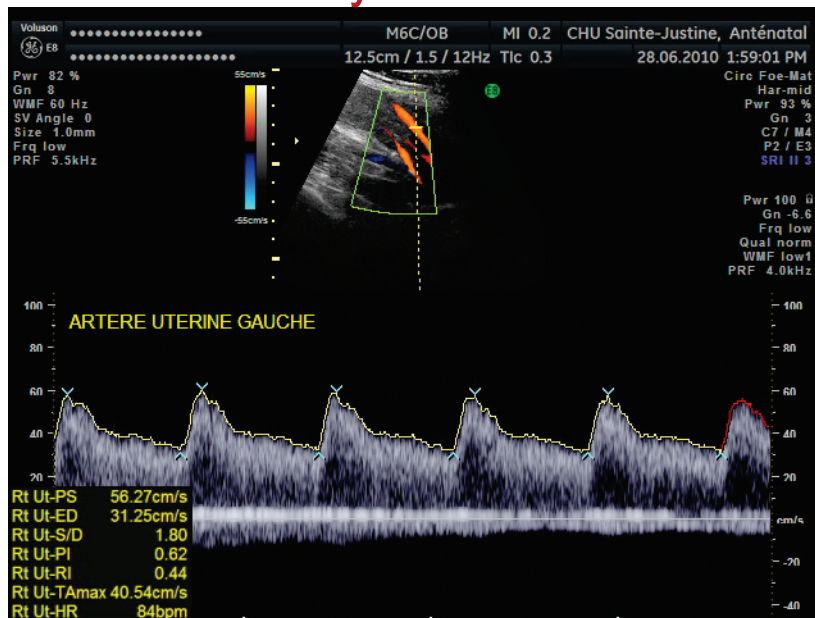
Uterines arteries

Normal recordings

Right uterine artery



Left uterine artery



Abnormal recording

Presence of a protodiastolic notch

